

# Postoperative Platysmal Band Deformity

## A Pitfall of Submental Liposuction

Frank M. Kamer, MD, John J. Minoli, MD

• Submental liposuction is an established advance in treatment of the aging neck. However, its misapplication may result in an aesthetic deformity involving postoperative anterior platysmal banding. To identify preoperative conditions relating to this sequela, we retrospectively analyzed 301 patients treated with submental liposuction. Submental obesity and an anatomic pattern of platysmal nondecussation were found to be significant correlates in the development of postoperative anterior platysmal banding.

(*Arch Otolaryngol Head Neck Surg.* 1993;119:193-196)

Surgical rejuvenation of an aging face almost invariably incorporates treatment of the neck. The extent of treatment depends on a thorough assessment of the aging neck and its components, which may include skin inelasticity, fat deposition, excess muscle, anterior platysmal band development (cording, bowstringing), and micrognathia.<sup>1-4</sup> The surgical approach involves a combination of rhytidectomy with superficial musculoaponeurotic system (SMAS) retrodisplacement, lipectomy, and anterior platysmal band alteration. Two of the most common postoperative sequelae following submental surgical lipectomy are submental depression and anterior platysmal band deformity.<sup>5-8</sup> We have noted anterior platysmal band deformities that develop following submental liposuction, a phenomenon previously unreported in the scientific literature (Fig 1); consequently, we retrospectively analyzed 301 patients treated with submental liposuction in an effort to identify preoperative and operative conditions that may precipitate this deformity.

### PATIENTS, MATERIALS, AND METHODS

All patients treated with submental liposuction by one of us (F.M.K.) between January 1, 1988 and January 1, 1991 were subjects of a retrospective medical chart review. Each of the patients had been visually and digitally examined preoperatively with attention both to their preoperative facial/cervical photographs and to their submental anatomy in repose and with voluntary

muscle contracture. Surgical planning was designed to address three elements of the neck: fat, skin, and muscle. The surgical approach varied based on the condition of each of these elements in each patient.

Deposition of fat warranted submental/submandibular liposuction with 12- and 14-gauge blunt-tipped rounded cannulae connected to an aspirator (Multipurpose Aspirator, Dean Medical Instruments Inc, Carson, Calif) set at 75 cm Hg. Redundant skin was treated with wide undermining of the skin-subcutaneous musculoaponeurotic system, SMAS retrodisplacement, and rhytidectomy. Preoperative anterior platysmal bands were managed by transection through a lateral skin flap when minimal and by midline transection and plication through a submental incision when moderate to severe as outlined by Kamer and Lefkoff.<sup>3</sup> Corrective surgery of postoperative platysmal band deformities involved direct platysmal transection/plication in the midline through a submental crease incision,<sup>3</sup> performed under local anesthesia (Fig 2).

All patients were followed up for a minimum of 1 year and a maximum of 4 years. Postoperative facial/cervical photographs were taken between 6 months and 1 year following surgery. Review of the medical chart involved analysis of preoperative and postoperative examination records and postoperative photographs.

### RESULTS

The 301 patients in our study can be divided into four groups based on the variety of surgical techniques applied to them (Table 1). Eighteen patients were treated by liposuction alone; 13 were treated by liposuction and rhytidectomy, but no SMAS retrodisplacement; 216 were treated by liposuction, rhytidectomy, and SMAS retrodisplacement; and 54 were treated by liposuction, rhytidectomy, SMAS retrodisplacement, and direct platysmal band surgery.<sup>9,10</sup> Twenty patients had development of an anterior platysmal band deformity postoperatively—19 of whom had undergone liposuction, rhytidectomy, and SMAS retrodisplacement, and one of whom had undergone liposuction and rhytidectomy only. None of the patients had development of submental depression postoperatively.

Further analysis of the 20 patients with postoperative banding deformity revealed definite trends (Table 2). On review, 18 of the 20 appeared to have preoperative evidence of moderate anterior platysmal banding; the two that did not had preoperative evidence of excessive submental fat. All 20 patients presented to initial surgery with redundant skin and jowling. Hyoid bone position was

Accepted for publication July 10, 1992.

From the UCLA School of Medicine, Los Angeles, Calif.

Read before the Western Regional Meeting of the American Academy of Facial Plastic and Reconstructive Surgery, Beverly Hills, Calif, February 1, 1992.

Reprint requests to 201 S Lasky Dr, Beverly Hills, CA 90212 (Dr Kamer).

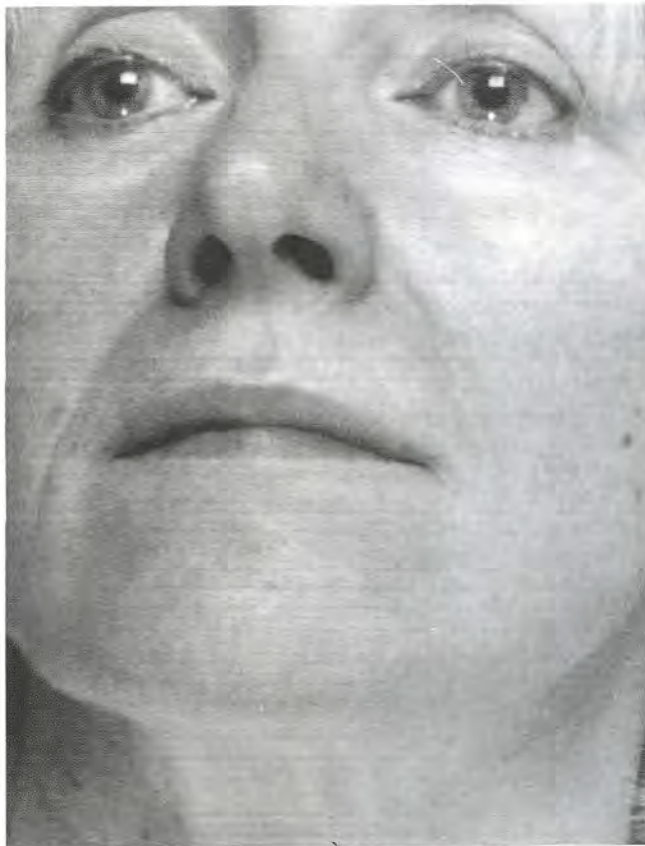

Fig 1.—Demonstration of anterior platysmal band deformity 4 years after submental liposuction.

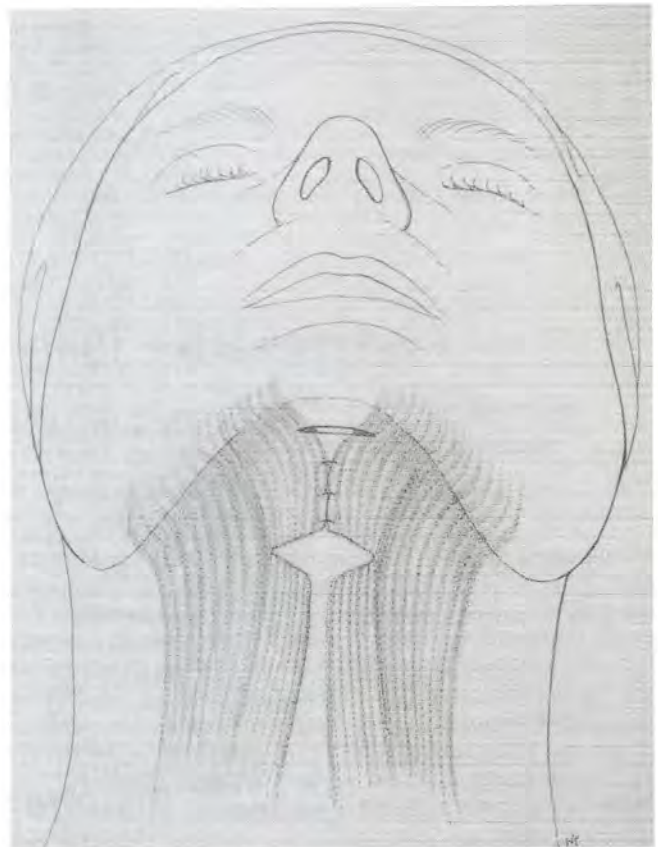


Fig 2.—Direct platysmal transection/plication in the midline through a submental crease incision (from Kamer and Lefkoff<sup>3</sup>).

Table 1.—Correlation of Surgery and Postoperative Banding Deformity

Group*	No. of Patients Undergoing Primary Surgery	Resulting No. (%) of Patients With Postoperative Anterior Platysmal Band Deformity
A	18	0
B	13	1 (7.7)
C	216	19 (8.8)
D	54	0
<b>Total</b>	<b>301</b>	<b>20 (6.6)</b>

\*Group A indicates submental liposuction only (no rhytidectomy); group B, submental liposuction and rhytidectomy (no superficial musculoaponeurotic system [SMAS] retrodisplacement); group C, submental liposuction, rhytidectomy, and SMAS retrodisplacement; and group D, submental liposuction, rhytidectomy, SMAS retrodisplacement, and direct platysmal band surgery.

variable, eight patients having a normal alignment and 12 having a low-lying or indeterminate alignment.

All 20 patients with postoperative banding deformity were offered corrective surgery, a relatively simple outpatient procedure performed under local anesthesia. Only seven of the 20 opted for correction. The remainder thought their deformity too minimal to require further surgery. All seven exhibited an undecussated pattern of the anterior platysmal sheets at the time of correction. None of the seven required further revision, each having been followed up for at least 1 year (Fig 3).

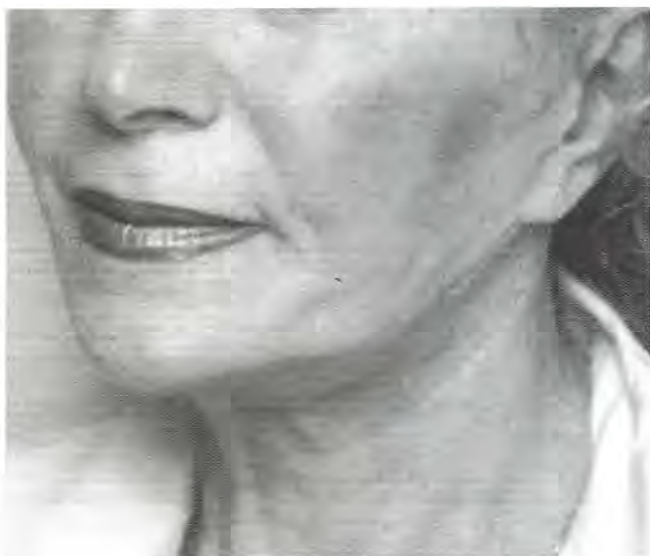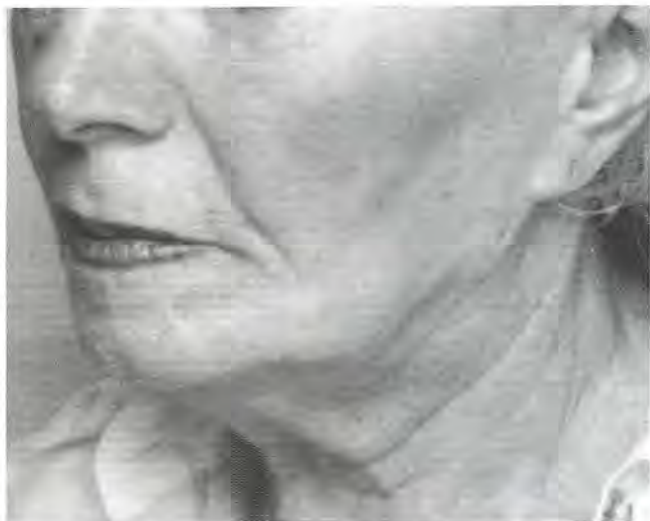Table 2.—Preoperative Features of Patients in Whom Postoperative Anterior Platysmal Band Deformity Developed

	No.
Neck classification <sup>3</sup>	
Excessive submental fat, redundant skin (class 2 neck)	2
Moderate anterior platysmal bands, redundant skin (class 3 neck)	18
Hyoid bone position	
Normal	8
Low or indeterminate	12

## COMMENT

Surgical correction of the aging neck has been developing amidst controversy for 70 years. Between 1919 and 1936, Bourguet pioneered the application of cervical lifting, submental lipectomy, platysmal band transection, and the description of platysmal variants (ie, midline interdigitating and non-interdigitating patterns).<sup>11</sup> In 1932, Maliniak outlined a corrective lipectomy for double chin deformity,<sup>12</sup> while in 1946, Padgett and Stephenson described the imbrication of platysmal fibers in the midline for the same problem.<sup>13</sup> Curettage of submental fat was then briefly referenced by Davis<sup>14</sup> in 1955. By 1963, Marino and colleagues<sup>15</sup> expanded preoperative analysis of the "double chin" with radiologic and clinical correlations of hyoid bone position. Adamson and associates<sup>16</sup> followed in 1964 with a study on surgical correction of the "turkey gobbler"

Platysmal Band Deformity—Kamer & Minoli



**Fig 3.**—*Top, Preoperative view of a patient with moderate platysmal banding. Center, Six months after submental liposuction, rhytidectomy, and superficial musculoaponeurotic system retrodisplacement; postoperative banding deformity is evident. Bottom, Six months after corrective band surgery; resolution of postoperative banding deformity is evident.*

deformity in which they forwarded the concept of anterior or cervical lipectomy and midline plication of platysmal fibers. In 1979, Vistnes and Souther<sup>1</sup> contributed results of anatomic studies in cadavers and patients, concluding that anterior neck bands are related strictly to patients with an undecussated platysma in the midline of the neck and further suggesting that this incidence in the population approximates 40%. Other concepts of repairing the aging neck have included skin excision via Z-plasty and W-plasty,<sup>17,18</sup> skin and fat excision through an "H" incision with one vertical and two horizontal lines,<sup>19</sup> submandibular lipectomy,<sup>20</sup> anterior platysmal band excision,<sup>21</sup> Z-plasty of anterior platysmal bands,<sup>22</sup> and mobilization of platysmal muscle slings.<sup>23,24</sup> Many of these procedures lost favor after revelation of postoperative deformities, such as submental dimpling and noticeable incisional scarring.<sup>6</sup>

Today, modifications of midline platysmal transection and plication are advocated widely.<sup>3,8</sup> Along with this trend, liposuction has largely supplanted surgical lipectomy for treatment of submental fat.<sup>25-28</sup>

This history of surgical developments is replete with reports of untoward postoperative sequelae—most particularly submental depression and anterior platysmal band deformity.<sup>5-8</sup> Many methods have been utilized to deal with these deformities, including placement of dermal and fat grafts into the submentum and platysmaplasty in various forms.<sup>3,5,8</sup> Although it is generally understood that skin sagging and redundancy may result following liposuction, no definitive studies have related submental liposuction to postoperative anterior platysmal band deformity.

Of the 301 patients studied, 20 (6.6%) had development of bands after submental liposuction; seven of those patients sought revision. At reoperation, all deformities were associated with a midline pattern of platysmal nondecussation—this corresponding with the earlier data of Vistnes and Souther<sup>1</sup> that anterior platysmal band formation exists only in concert with an undecussated muscle. We cannot comment on the anatomic pattern of the 13 patients with deformity who declined revision. Of note, each of the 13 believed the postoperative deformity was of minor consequence and did not mandate correction.

The common preoperative findings among patients who had development of postoperative deformities were redundant skin and mild preoperative banding; hyoid bone position did not seem to be a significant factor. This suggests a correctable situation given the appropriate choice of platysmal transection/plication procedures at primary surgery. Of significance, the bulk of this group (19 of 20 patients) had SMAS retrodisplacement at initial surgery but still had development of anterior platysmal band deformity postoperatively, suggesting that no amount of retrodisplacement of the lateral SMAS border will address a problem that is primarily situated in or near the midline; the intraoperative appearance may hint otherwise, but the seeming resolution of midline irregularities at initial surgery is almost invariably short lived. We believe that if anterior platysmal banding exists preoperatively, it must be dealt with directly during initial surgery. Creation of an anterior

muscle sling via midline transection/plication establishes an uninterrupted platysmal sheet that seems to eliminate the potential for postoperative banding. This is supported by the finding that none of our patients who had direct platysmal band surgery had development of the deformity.

Patients with submental obesity represent a special diagnostic dilemma. Despite ideal preoperative assessment, they may elude diagnosis until the deformity prevails during postoperative healing as happened in two of our patients. In these two patients, excess submental fat concealed the undecussated platysma and submental liposuction only served to skeletonize and scarify the very anatomic pattern predisposed to postoperative banding.

In summary, our retrospective analysis of patients who have undergone submental liposuction demonstrates the potential for postoperative anterior platysmal band deformity, particularly in those patients with redundant cervical skin, mild preoperative bands, and submental obesity. In our series of patients, an undecussated platysma was always associated with this deformity. At revision surgery, midline transection/plication of the bands uniformly corrected the problem in a simple manner.

#### References

1. Vistnes LM, Souther SG. The anatomical basis for common cosmetic anterior neck deformities. *Ann Plast Surg.* 1979;2:381-388.
2. Souther SG, Vistnes LM. Medial approximation of the platysma muscle in the treatment of neck deformities. *Plast Reconstr Surg.* 1981;67:607-613.
3. Kamer FM, Lefkoff LA. Submental surgery: a graduated approach to the aging neck. *Arch Otolaryngol Head Neck Surg.* 1991;117:40-46.
4. Ellenbogen R, Karlin JV. Visual criteria for success in restoring the youthful neck. *Plast Reconstr Surg.* 1980;66:826-837.
5. Wilkinson TS. The repair of a submental depression occurring after rhytidectomy. *Plast Reconstr Surg.* 1976;57:33-35.
6. Kamer FM, Binder WJ. Avoiding depressions in submental lipectomy. *Laryngoscope.* 1980;90:1396-1400.
7. Ellenbogen R, Karlin JV. Regrowth of platysma following platysma cervical lift: etiology and methodology of prevention. *Plast Reconstr Surg.* 1981;67:616-623.
8. Feldman JJ. Corset platysmaplasty. *Plast Reconstr Surg.* 1990;85:333-343.

9. Skoog T. The aging face. In: Skoog T, ed. *Plastic Surgery: New Methods and Refinements.* Philadelphia, Pa: WB Saunders Co; 1974:300-330.
10. Kamer FM, Hunter D. The two layer, four flap rhytidectomy technique. *Laryngoscope.* 1981;91:829-832.
11. Marchac D. Julien Bourguet: the pioneer in aesthetic surgery of the neck. *Clin Plast Surg.* 1983;10:363-365.
12. Maliniak JW. Is the surgical restoration of the aged face justified? *Med J Rec.* 1932;135:321-324.
13. Padgett EC, Stephenson KL. Reconstructive surgery of the neck. In: Padgett EC, Stephenson KL, eds. *Plastic and Reconstructive Surgery.* Springfield, Ill: Charles C Thomas Publisher; 1946:638.
14. Davis AD. Obligations in the consideration of meloplasties. *J Int Coll Surg.* 1955;24:567-571.
15. Marino H, Galeano EJ, Gandolfo EA. Plastic correction of double chin. *Plast Reconstr Surg.* 1963;31:45-50.
16. Adamson JE, Horton CE, Crawford HH. The surgical correction of the "turkey gobbler" deformity. *Plast Reconstr Surg.* 1964;34:598-605.
17. Picaud AJ. Les differentes formes d'incisions et les techniques de face-lifting, selon l'age, le formes de visages et l'etat des teguments. In: Sanvenero-Rosselli G, ed. *Transactions of the Fourth International Congress of Plastic and Reconstructive Surgery.* Amsterdam, the Netherlands: Excerpta Medica Foundation; 1969:1108-1115.
18. Cannon B, Pantazelos HH. W-Plasty approach to submandibular lipectomy. In: Hueston JT, ed. *Transactions of the Fifth International Congress of Plastic and Reconstructive Surgery.* Woburn, Mass: Butterworths; 1970:1113-1117.
19. Morel-Fatio D. Cosmetic surgery. In: Gibson T, ed. *Modern Trends in Plastic Surgery.* Woburn, Mass: Butterworths; 1964:216-222.
20. Millard DR, Pigott RW, Hedo A. Submandibular lipectomy. *Plast Reconstr Surg.* 1968;41:513-522.
21. Millard DR, Garst WP, Beck RL, Thompson ID. Submental and submandibular lipectomy in conjunction with a face lift, in the male or female. *Plast Reconstr Surg.* 1972;49:385-391.
22. Weisman PA. Simplified technique in submental lipectomy. *Plast Reconstr Surg.* 1971;48:443-446.
23. Guerrero-Santos J, Espaillet L, Morales F. Muscular lift in cervical rhytidoplasty. *Plast Reconstr Surg.* 1974;54:127-131.
24. Connell BF. Cervical lifts: the value of platysma muscle flaps. *Ann Plast Surg.* 1978;1:34-43.
25. Illouz YG. Body contouring by lipolysis: a 5-year experience with over 3000 cases. *Plast Reconstr Surg.* 1983;72:591-597.
26. Teimourian B. Face and neck suction-assisted lipectomy associated with rhytidectomy. *Plast Reconstr Surg.* 1983;72:627-633.
27. Avelar J. Fat-suction of the submental and submandibular regions. *Aesthetic Plast Surg.* 1985;9:257-263.
28. Courtiss EH. Suction lipectomy of the neck. *Plast Reconstr Surg.* 1985;76:882-889.